CASE REPORT

Oman Medical Journal [2026], Vol. 41, No. 4: e865

Undifferentiated Pleomorphic Sarcoma of the Testis with Focal Myogenic Differentiation: A Case Report

Noor Nabi Junejo[1]*, Najib AbuDraz[1], Bayan Al Alawi[1], Salim Al Maqbali[1], Shahid Aquil[1], Fathiya Al Rahbi[2] and Khurram Mutahir Siddiqui[1]

[1]Department of Urology, Sultan Qaboos University Hospital, Muscat, Oman
[2]Department of Pathology, Sultan Qaboos University Hospital, Muscat, Oman

ARTICLE INFO

Article history:
Received: 23 November 2023
Accepted: 26 December 2023

Online:
DOI 10.5001/omj.2026.11

Keywords:
Testis; Sarcoma; Oman.

ABSTRACT

Undifferentiated pleomorphic sarcoma (UPS) of the testis is an extremely rare entity. We present a case of UPS in a 68-year-old man who presented with a left testicular solid mass and underwent left radical orchiectomy. Histopathology showed undifferentiated pleomorphic sarcoma with focal myogenic differentiation. At six-month follow-up, the patient was disease-free. Surgical management with radical orchiectomy is the preferred treatment. The role of postoperative radiotherapy and chemotherapy remains unclear. To our knowledge, this is the first case of UPS from Oman.

Undifferentiated pleomorphic sarcoma (UPS) is a rare soft tissue sarcoma that affects deep tissues, often in old age.[1] UPS was previously known as malignant fibrous histiocytoma (MFH), which is considered a more general term, including several other sarcomas such as UPS.[2] The extremities are the most affected sites with undifferentiated high-grade pleomorphic sarcomas.[1,3,4] UPS is reported to have a worse prognosis than other types of MFH.[5]

Another condition with histological similarity to UPS is myxofibrosarcoma (MFS). Though UPS and MFS were classified in 2002 as separate entities based on their clinical pathologies,[6] comprehensive and integrated genomics have shown that UPS and MFS are largely indistinguishable in a cross-platform molecular context.[7] Thus, UPS/MFS remain a headache in clinical practice. We report a rare case, which was diagnosed as testicular UPS.

CASE REPORT

The patient was a 68-year-old married man, non-smoker, with a surgical history of coronary artery bypass grafting a decade ago, and a left hydrocelectomy a year ago. He presented to our urology clinic in March 2023, with complaints of a progressively growing left testicular swelling and mild pain for five months. On palpation, the left testis had a craggy texture suggest a large epididymal swelling. There were no local signs of inflammation or hernia.

A contrast-enhanced CT of the abdomen and pelvis revealed a heterogeneous left paratesticular mass with no inguinal or para-aortic lymphadenopathy [Figure 1]. An MRI showed a heterogeneous mass (5.1 × 5.2 cm) in the left testicle. The mass showed high signal intensity on both T1- and T2-weighted images and had regions of diffusion restriction [Figure 1].

The mass appeared to be arising from the epididymis. Significantly increased vascularity was also apparent within the spermatic cord, extending from the inguinal region down to the mass and epididymis. There was no obvious invasion of the scrotal wall. The right testicle appeared normal. No significant inguinal lymph nodes, pelvic or retroperitoneal lymphadenopathy, or lung pathology were detected. All tumor markers—alpha-fetoprotein, beta human chorionic gonadotropin, and lactate dehydrogenase—were within normal ranges.

Therefore, based on clinical and radiological findings, the patient underwent a left radical inguinal orchiectomy and was discharged on the first post-operative day. At six-month and one-year follow-up, he remained free from any recurrence or metastasis of the disease.

The excised orchiectomy sample was subjected to histopathology. Gross pathological examination

*Corresponding author: ✉drnoorjunejo@gmail.com

Copyright © 2026, Oman Medical Journal

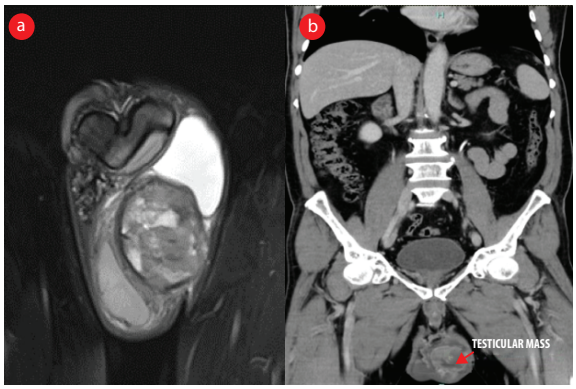

Figure 1: Solid heterogenous mass in the left testicle as seen in **(a)** MRI and **(b)** contrast-enhanced CT.



Figure 2: Gross pathological view of the orchiectomy sample showing a 5.5 × 5.4 × 3 cm well-delineated tumor with a tan solid surface originating from the epididymis.

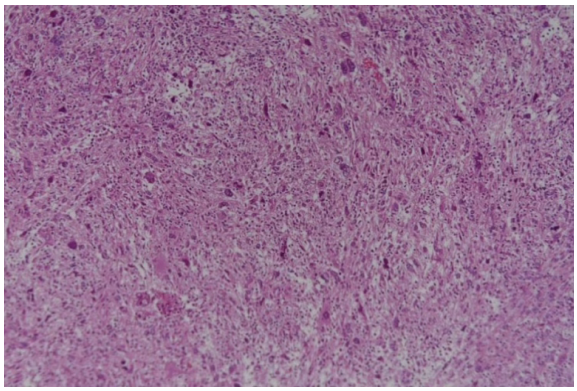

Figure 3: Hematoxylin and eosin-stained section showing highly pleomorphic tumor cells arranged in a storiform pattern, magnification = 10 ×.

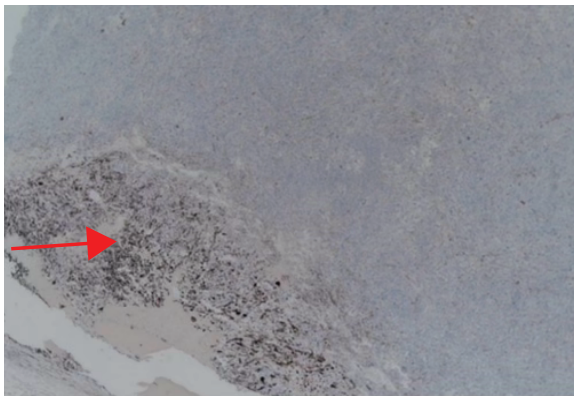

Figure 4: Tumor cell showing focal positive staining for desmin immunohistochemistry stain, magnification = 100 ×.

revealed a well-delineated tumor measuring 5.5 × 5.4 × 3 cm with a solid tan surface arising from the epididymis. On slicing, the testis was markedly atrophic (3.5 × 2.2 × 3 cm). The epididymis was seen replaced by a well-circumscribed mass (5.5 × 5.4 cm) with a necrotic yellow hemorrhagic surface [Figure 2]. Microscopically epididymal mass showed a malignant spindle cell neoplasm exhibiting fascicles of high-grade tumor cells with extensive tumor necrosis. The tumor cells had enlarged hyperchromatic nuclei with prominent nucleoli and spindly cytoplasm. The mitotic rate was variable and measured up to 25 mitotic figures per 10 high-power fields. Marked cytological atypia was present with tumor-type giant cells. The French Federation of Cancer Centers Sarcoma Group grading system score was 8/8 (3 for degree of differentiation, 2 for necrosis, and 3 for no lymphovascular space invasion). Microscopy showed highly pleomorphic tumor cells arranged in a storiform pattern [Figure 3]. Immunohistochemistry revealed focal expression of desmin and caldesmon [Figure 4].

The histopathology report concluded that the morphology and immunophenotype findings were in keeping with UPS with focal myogenic differentiation. The pathological stage of the tumor was determined as pT2 (TNM 8th edition). The tumor was classified as grade 3 as per the French Federation of Cancer Centers Sarcoma Group system. Verbal consent for publication was obtained from the patient.

DISCUSSION

Only about 1–2% of all testicular tumors are malignant. Even among the latter, testicular UPS are among the rarest. To our knowledge only four cases of testicular UPS were documented by 2013: one from England and two from China, in men aged 56–78 years.[4] Other studies reported ages ranging

from 14 to 78 years at the initial presentation with MFH of the testis.[4,5,8-11] The diagnosis of UPS is challenging and is usually one of exclusion, which has to be confirmed by postoperative examination and histological study.[5,12] The treatment of sarcoma is surgical resection of the mass with or without radiotherapy.[5,12] The microscopic findings of pleomorphic cells with multinucleated giant cells in our patient were also reported by other studies.[5,12,13]

It is important to review the specimen for desmin and caldesmon,[5,12] which were positive in our patient. The low Ki-67 expression also differentiated our case from others which reported high expression of Ki-67.[4,7,11] Postsurgical radiotherapy is reported to reduce the chances of local recurrence, with Nascimento et al,[14] reporting positive response of 55% and 66%.[11] Radiotherapy was not required in the current case, as the resection margin was free of pathology.

CONCLUSION

UPS is a rare testicular tumor. The first-line of management is radical orchiectomy. Adjuvant chemotherapy is advisable to improve survival, if indicated.

Disclosure

The authors declare no conflicts of interest.

REFERENCES

1. Robles-Tenorio A, Solis-Ledesma G. Undifferentiated pleomorphic sarcoma. [Updated 2023 Apr 10]. In: StatPearls [Internet]. Treasure Island (FL): StatPearls Publishing; 2024 Jan. 2025 [cited 2024 January 13]. Available from: https://www.ncbi.nlm.nih.gov/books/NBK570612.
2. O'Brien JE, Stout AP. Malignant fibrous xantomas. Cancer 1964 Nov;17(11):1445-1455.
3. Malik AT, Baek J, Alexander JH, Voskuil RT, Khan SN, Scharschmidt TJ. Malignant fibrous histiocytoma of bone: a survival analysis from the national cancer database. J Surg Oncol 2020 Jun;121(7):1097-1103.
4. Wang LL, Xie H, Fu HL, Jiang S, Wang XF, Jia MZ, et al. An adolescent presenting with malignant fibrous histiocytoma of the testis: a case report. J Med Case Rep 2013 Jan;7:30.
5. Ülker V, Atalay HA, Çakır Ç, Sargan A. Giant malignant fibrous histiocytoma of the testis. Turk J Urol 2018 Jan;44(1):79-81.
6. Hu Q, Zhou S, Hu X, Zhang H, Huang S, Wang Y. Systematic screening identifies a 2-gene signature as a high-potential prognostic marker of undifferentiated pleomorphic sarcoma/myxofibrosarcoma. J Cell Mol Med 2020 Jan;24(1):1010-1021.
7. Lazar AJ, McLellan MD, Bailey MH, Miller CA, Appelbaum EL, Cordes MG, et al. Comprehensive and integrated genomic characterization of adult soft tissue sarcomas. Cell 2017 Nov;171(4):950-965.
8. Staiman VR, O'Toole KM, Rubin MA, Lowe FC. Giant malignant fibrous histiocytoma of the testis/spermatic cord: psychologic and possible etiologic complications of unethical Nazi medical experimentation. Urology 1996 Dec;48(6):939-943.
9. Miyagi T, Ohtaki M, Rin S, Matsubara F. [Intrascrotal malignant fibrous histiocytoma: a case report and review of the literature]. Hinyokika Kiyo 1985 Mar;31(3):527-532.
10. Hinev A. [Malignant fibrous histiocytoma of the epididymis]. Cir Esp 2010 Mar;87(3):195-196.
11. Le Doussal V, Coindre JM, Leroux A, Hacene K, Terrier P, Bui NB, et al. Prognostic factors for patients with localized primary malignant fibrous histiocytoma: a multicenter study of 216 patients with multivariate analysis. Cancer 1996 May;77(9):1823-1830.
12. Mathew R, Sethi A, Flint AT, Omman R, House J. A case of undifferentiated pleomorphic sarcoma. Cureus 2022 Jun;14(6):e26153.
13. Han JP, Luo WX, Zeng JW, Ma WX, Zhao Q, Xie YQ, et al. Recurrent testicular undifferentiated pleomorphic sarcoma. Asian J Androl 2023;25(4):541-543.
14. Nascimento AF, Raut CP. Diagnosis and management of pleomorphic sarcomas (so-called "MFH") in adults. J Surg Oncol 2008 Mar;97(4):330-339.